



PRESENTING CLINICAL SIGNS

DATE History: Grade 3/6 murmur. Asymptomatic.

ECHOCARDIOGRAPHIC FINDINGS

7/27/22 2D, M-mode, and Doppler study.

PERFORMED BY: Left atrial size is normal. The mitral valve leaflets are mildly thickened and exhibit mild systolic prolapse. A mild jet of eccentric mitral regurgitation is present. Left ventricular dimensions are normal. Left ventricular systolic function is hyperdynamic. The aorta and aortic valve are normal. Right atrial and right ventricular dimensions are normal. The tricuspid valve is normal. The pulmonary artery and pulmonic valve are normal. No pericardial effusion or cardiac masses are seen.

Loetitia Saint-Jacques, RVT

INTERPRETED BY

Keith Blass, DVM, MS, DACVIM (Cardiology)

LA - 31.0 mm
LVIDd - 27.5 mm
LVIDs - 13.2 mm
FS - 52%
RA - 20.2 mm
LVOT - 1.67 m/s
RVOT - 1.34 m/s

PATIENT

Ginger Zubertz

ASSESSMENT/RECOMMENDATIONS

Degenerative mitral valve disease

SPECIES

Canine

This examination demonstrates mild regurgitation of blood across Ginger's mitral valve resulting from degenerative valve disease. The hemodynamic effects of the regurgitation also appear to be mild, as Ginger does not have secondary dilation of either of her left heart chambers, and her left ventricular systolic function is well-preserved. As such, Ginger's mitral valve disease appears to be well-compensated, and her current risk for the development of clinical signs secondary to it, such as coughing, exercise intolerance, syncope, and labored breathing, appears to be low.

BREED

Beagle Mix

No therapy is recommended at this stage of disease.

SEX

FS

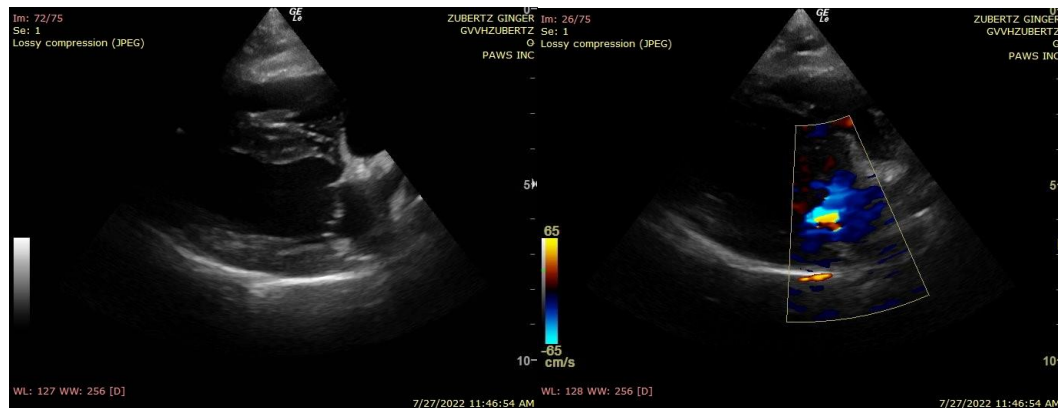
A recheck echocardiogram is recommended in 6 months to monitor for disease progression.

AGE

13 y

WEIGHT

25 lb



HOSPITAL NAME

Grass Valley

REFERRING VET

Dr. Michaelis



DATE

7/27/22

The information and recommendations provided are based on the images presented by the referring veterinarian. No evaluation can be communicated regarding pathology that was not visible in the image/video clips provided.

PERFORMED BY:

Loetitia Saint-Jacques, RVT

Thank you for this referral. If the clinical or image interpretation does not parallel your findings or if I can be of any further assistance please contact me.

INTERPRETED BY

Keith Blass, DVM, MS, DACVIM (Cardiology)
KeithBlass@gmail.com
631-804-5754

Keith Blass, DVM,
MS, DACVIM
(Cardiology)

PATIENT

Ginger Zubertz

SPECIES

Canine

BREED

Beagle Mix

SEX

FS

AGE

13 y

WEIGHT

25 lb

HOSPITAL NAME

Grass Valley

REFERRING VET

Dr. Michaelis